

INTRABONY DEFECTS TREATED WITH A COMBINATION OF α -TRICALCIUMPHOSPHATE AND AN OILY CALCIUM HYDROXIDE SUSPENSION. A CASE SERIES

Stefan-Ioan Stratul¹, Britta Willershausen², Anton Sculean²

REZUMAT

Un preparat uleios conținând hidroxid de calciu s-a dovedit în ultimii ani a fi deosebit de eficient în promovarea regenerării osoase în defecte închise de tipul leziunilor cronice periapicale, în chiste, defecte postextractionale. Scopul acestui studiu este prezentarea pe o serie de cazuri a tehnicii chirurgicale și a rezultatelor clinice consecutiv tratamentului defectelor infraosoase profunde parodontale cu o combinație de alfa-TCP și suspensia uleioasă de hidroxid de calciu. 14 pacienți, fiecare prezentând câte un defect infraosos profund, au fost tratați cu combinația dintre alfa-TCP (BioBase® α -pore, Biovision GmbH., Ilmenau, Germania) și suspensia uleioasă de hidroxid de calciu (Osteoinductal®, Osteoinductal GmbH, Muenchen, Germania). Vindecarea postoperatorie a fost excelentă. Măsurătorile clinice la 6 luni de la tratament au relevat o reducere medie a adâncimilor de sondaj (PPD) de la $7,93 \pm 1,44$ mm la $3,7 \pm 1,69$ mm și o modificare a atașamentului clinic (CAL) de la $8,07 \pm 1,44$ mm la $4,21 \pm 1,81$ mm, în timp ce recesia gingivală medie (GR) a crescut de la $0,14 \pm 0,53$ mm la $1,29 \pm 1,38$ mm. Afăt scăderea adâncimii de sondaj cât și câștigul de atașament clinic au fost semnificative din punct de vedere statistic, în comparație cu nivelul de bază ($p < 0,001$). Rezultatele clinice obținute indică faptul că folosirea în combinație a celor două materiale poate să conducă la scăderi semnificative de PPD și la câștiguri statistic semnificative de CAL. Deoarece dovezile histologice ale vindecării obținute prin această terapie sunt încă așteptate, validarea acestei combinații în tratamentul defectelor profunde infraosoase va necesita în continuare efectuarea de studii clinice controlate, care să elucideze gradul în care această abordare poate îmbunătăți rezultatele clinice, în comparație cu monoterapiile corespunzătoare.

Cuvinte cheie: suspensie uleioasă de hidroxid de calciu, α -TCP, regenerare periodontală

ABSTRACT

An oily Calcium Hydroxide formulation proved over the last years to be highly efficient in promoting bone regeneration in closed defects as periapical lesions, cysts, or postextraction defects. Aim of this study is the presentation on a case series of the surgical technique and of the clinical results after the treatment of deep intrabony periodontal defects with a combination of Alpha-TCP and an oily suspension of Calcium Hydroxide. Fourteen patients, each with a deep intrabony defect were treated with a combination of Alpha-TriCalcium Phosphate (BioBase® α -pore, Biovision GmbH., Ilmenau, Germany) and oily Calcium Hydroxide suspension (Osteoinductal®, Osteoinductal GmbH., Muenchen, Germany). An excellent postoperative healing was noticed. The clinical measurements six months after the treatment revealed a reduction of the probing pocket depth (PPD) from 7.93 ± 1.44 mm to 3.7 ± 1.69 mm, and a change of the mean clinical attachment level (CAL) from 8.07 ± 1.44 mm to 4.21 ± 1.81 mm, while the mean gingival recession (GR) changed from 0.14 ± 0.53 mm to 1.29 ± 1.38 mm. Both the PPD and CAL changes were statistically significant compared to baseline ($p < 0.001$). The clinical results indicate that the combination of the two materials may lead to significant PPD reductions and CAL gains. As histological evidences of the healing obtained by this therapy are still expected, further validation of this combination in treatment of deep intrabony lesions will need controlled clinical studies, in order to elucidate whether this approach can improve the clinical outcomes, when compared to each single treatment.

Key Words: oily Calcium Hydroxide suspension, α -TCP, periodontal regeneration

INTRODUCTION

Results of basic research and clinical studies have proven the influence of an oily Calcium Hydroxide suspension (OCHS) on bone regeneration in closed defects subsequent to periapical surgeries, in bone cysts and postextraction alveolae.^{1,2} Its osteostimulative effect seems to rely on many factors, as the deposit action of the Calcium Hydroxide, which sustains the bone metabolism in a constant, mild alkali environment, the stimulation of the angiogenetic bone growth with concentration of the growth factors next to the defect wall, and the reduction of the inflammation in the

¹ Department of Odontology-Periodontology, Faculty of Dental Medicine, Victor Babes University of Medicine and Pharmacy, Timisoara, Romania

² Department of Conservative Dentistry and Periodontology, Section of Periodontology, Johannes Gutenberg-University, Mainz, Germany

Corresponding author:

Stefan Ioan Stratul, Department of Odontology-Periodontology, Faculty of Dental Medicine, Victor Babes University of Medicine and Pharmacy, Piata Eftimie Murgu 2, Timisoara, Romania
Email: sbs@online.ro

Received for publication: Nov. 15, 2004. Revised: Dec. 3, 2004.

operated site, which enhances the wound healing.^{1,3} Histological and radiological analysis, both in animals and humans seem to indicate a predictable regeneration of closed bone defects⁴. Such results recently led to attempts to use the oily Calcium Hydroxide suspension, alone or under various combinations, in treating periodontal defects.

Recently, a histology study in humans indicated that the treatment of chronic periodontal defects with OCHS alone could lead to the formation of a new attachment (cement with inserting collagen fibers) and alveolar bone.⁵ It has been also reported that the OCHS stimulates not only the bone formation, but also could inhibit the proliferation of epithelial cells.¹ It has been assumed that the OCHS could act by concentrating the growth factors next to the defect wall, thus preventing their dilution towards the center of the defect.^{6,7} The treatment of intrabony defects with OCHS clinically resulted in significant reductions of the probing depths and gains of clinical attachment level.⁸ The obtained results were significantly superior to those achieved by conventional access flap surgery, and were comparable with those achieved after the treatment with enamel matrix proteins⁹ and with guided tissue regeneration (GTR).¹⁰ A frequent complication of the GTR therapy is the exposure of the membrane with the subsequent bacterial contamination and even infection of the operated site.^{11,12} Such complications could negatively influence the post-operative healing and could even jeopardize the overall outcome of the therapy.^{11,12} The above mentioned complication does not occur in case of the OCHS therapy, and the postoperative healing seems to occur completely eventless in most of the cases.^{6,9, 13-16} However, from clinical point of view, some practical problems could arise when using the OCHS alone: the material has a low consistency and, therefore, cannot ensure a sufficient stability of the mucoperiosteal flap, especially in one-wall and circular defects. Frequently, a collapse of the mucoperiosteal flap cannot be avoided, followed by the reduction of the space necessary for the regeneration process.^{11,12}

To overcome such inconveniences, the combination of the OCHS with a bone replacement material could offer a convenient solution. By this approach, the chemical and biological properties of the OCHS could be combined with the mechanical properties of the bone replacement material. In this combination, the OCHS could enhance the bone and the periodontal healing, while the bone replacement material could avoid the collapse of the mucoperiosteal flaps and ensure the post-surgical stability of the wound.

Bone replacement materials could originate from various sources. It is well-known that autologous bone

harvested from intra- or extra-oral areas could provide the best results, being therefore regarded as the “golden standard” in the bone replacement procedures. Yet, the obtaining of such bone transplants often necessitate a second surgical intervention, that rarely complies with the routine-purpose of a periodontal intervention and with the availability and willingness of the patient to accept the transplant.¹⁷⁻¹⁹ There were assumptions (yet never clinically proven) that allografts and xenografts could involve the danger of transmission of viral diseases¹⁹.

Tricalcium phosphate (TCP) is a highly purified, multi-crystalloid, porous form of the Calcium phosphate. It is partially resorbable and is normally used for the repair of non-pathologic sites, in which the resorbtion of the implant and a replacement by bone is expected.²⁰ If the healing of the marginal periodontal defects is desired, TCP can provide repair similar to autologous bone.²¹

TCP is compatible to the host tissue.²²⁻²⁷ The healing of the periodontal wound occurs with bone ingrowth in the pores of the TCP.²⁸⁻³⁰ Histological analysis of the healing of the defects revealed rather a long-junction epithelium than a connective attachment.^{29,31,32}

The combination of the mechanic properties of the TCP with the biological and chemical features of the OCHS could be both of biologic and clinical interest. So far, there are no clinical data regarding the combined therapy of OCHS and TCP in the treatment of intrabony periodontal defects.

OBJECTIVE

Aim of the study is the presentation of the surgical technique and of the clinical results after the treatment of intrabony defects with a combination of Alpha-TCP and an oily suspension of Calcium Hydroxide.

MATERIALS AND METHODS

Fourteen patients (9 male and 5 female), between 26 and 42 years old, non-smokers, each displaying one deep intrabony defect, were treated with a combination of alpha-TCP (BioBase® α -pore Biovision GmbH, Ilmenau, Germany) and an oily Calcium Hydroxide suspension (Osteoinductal®, Osteoinductal GmbH, Muenchen, Germany). All patients underwent initial therapy one month prior to surgery. All patients were instructed and motivated to maintain a good oral hygiene level, verified by a reduction of the PI (Silness and Loe) < 1. Before surgery and six months after, the following clinical parameters were registered: the periodontal pocket

depth (PD), the gingival recession (GR) and the clinical attachment level (CAL). All measurements were performed with a rigid periodontal probe (PCP 12, Hu-Friedy), at six sites per tooth (buccal: mesiobuccal, central, distobuccal; oral: mesiooral, central, distooral). Radiographic examination was performed using the conventional RIO technique. For each patient, the highest measured value was taken into account and the mean PD, GR and CAL were calculated. The paired Student t-test was used to compare the differences between baseline values and values measured six months after. Surgery was performed under local anesthesia. A full thickness flap was raised after intrasulcular incision, without using release incisions. After removal of the granulation tissue, the exposed roots underwent thorough S/RP using ultrasonic devices and curettes. No resection surgery was performed, nor any root conditioning. Equal amounts of Osteoinductal® and BioBase® α -pore were mixed in a dappen dish to a putty consistency mixture, which was placed into the defects in direct contact with the rough, vital bone surface. The amount of mixture did not exceed the margins of the defect. Post surgical care included antibiotherapy for one week (3x500 mg Amoxicillin daily) and 0.2% Chlorhexidin (Plak-Out®, Santa Balanos, Greece) mouth rinses, twice a day, for the following four weeks, as well as gentle debridement of the operated area every second week, for two months.

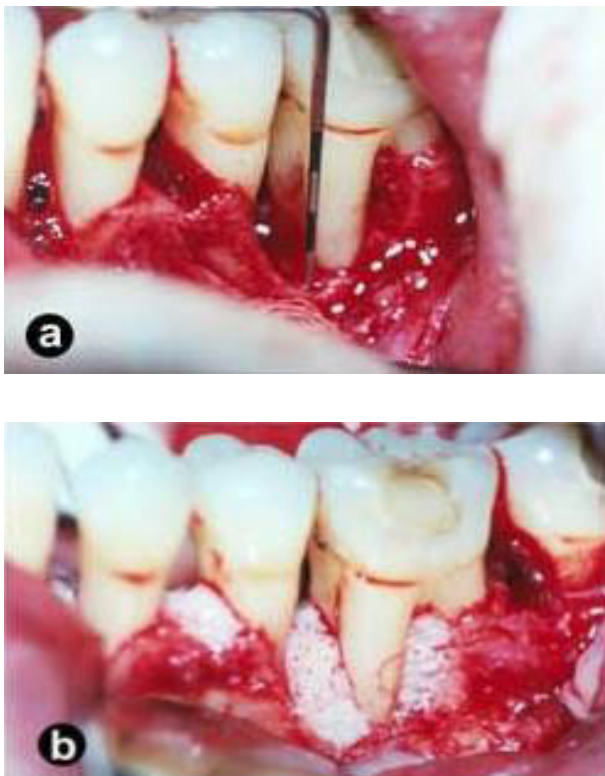


Figure 1. Case A; a) The bone defect exposed b) The mixture in situ

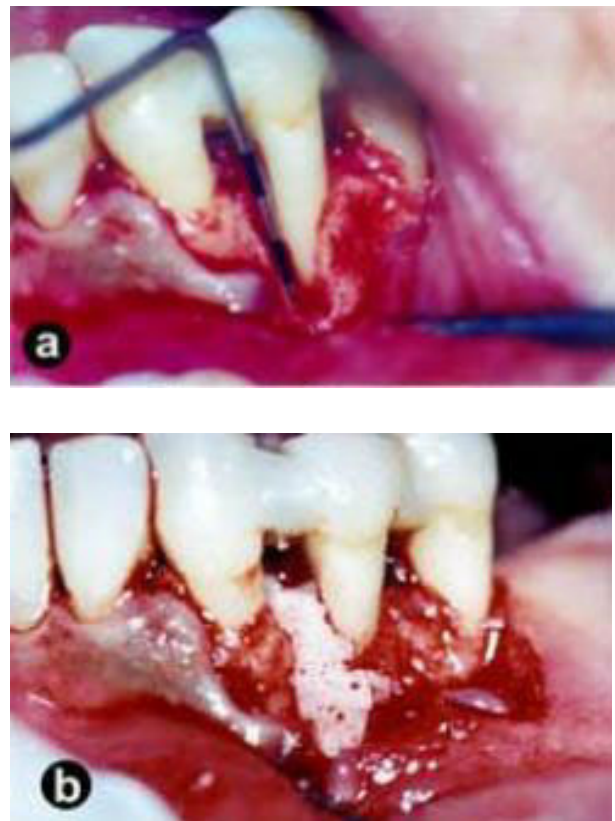


Figure 2. Case B; a) The bone defect exposed b) The mixture in situ

RESULTS

The healing phase progressed uneventful. No signs of inflammation, infection, allergy or severe pain were present. Pre-and postoperative mean values of the PD GR and CAL are displayed in Table 1.

Table 1.

Patient Nr.	Tooth Type	Defect Type (walls)	PPD (mm)			GR (mm)			CAL (mm)			CAL gain (mm)
			Pre-operative	After 6 months	Diff.	Pre-operative	After 6 months	Diff.	Pre-operative	After 6 months		
1	35	2	7	5	2	2	2	0	9	5	4	
2	13	2	10	2	8	0	1	1	10	3	7	
3	14	2	10	3	7	0	1	1	10	4	5	
4	15	3	8	1	7	0	3	3	8	4	4	
5	16	2	7	2	5	0	2	2	7	4	3	
6	33	3	9	2	7	0	0	0	9	2	7	
7	34	2	10	5	5	0	3	3	10	8	2	
8	35	2	7	1	6	0	4	4	7	5	2	
9	15	1	8	6	2	0	0	0	8	6	2	
10	12	2	7	1	6	0	0	0	7	1	6	
11	13	1	6	3	3	0	0	0	6	3	3	
12	46	2	7	3	4	0	0	0	7	3	4	
13	47	2	6	5	1	0	0	0	6	5	1	
14	11	1	9	4	5	0	2	2	9	6	3	
Mean			7.93	3.07	4.86	0.14	1.29	1.14	8.07	4.21	3.79	
SD			1.44	1.69	2.18	0.53	1.38	1.41	1.44	1.81	1.89	

The clinical measurements six months after treatment revealed a reduction of the probing pocket depth (PPD) from 7.93 ± 1.44 mm to 3.7 ± 1.69 mm, and a change of the mean clinical attachment level (CAL) from 8.07 ± 1.44 mm to 4.21 ± 1.81 mm, while the mean gingival recession (GR) increased from 0.14 ± 0.53 mm to 1.29 ± 1.38 mm. Both the PPD and CAL changes were statistically significant compared to baseline ($p < 0.001$). (Table 2)

Table 2. Mean and SD of the differences of the PD, GR and CAL and their statistical significance.

Difference	mean	SD	p
PPD	4.86	2.18	0.00
GR	1.14	1.41	0.17
CAL	3.79	1.89	0.00

Examination of Rx reveals a visible defect fill in all treated cases

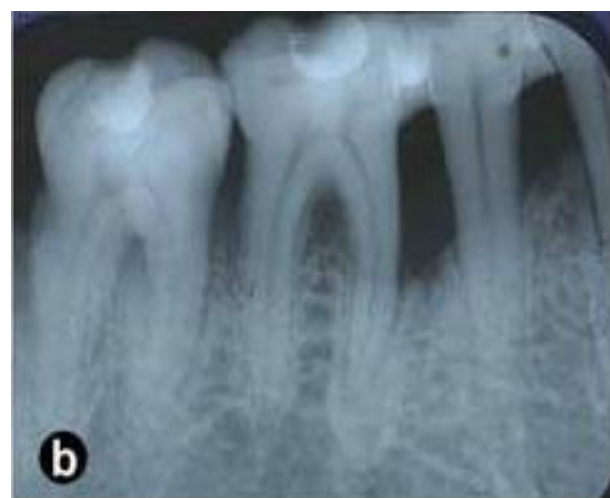
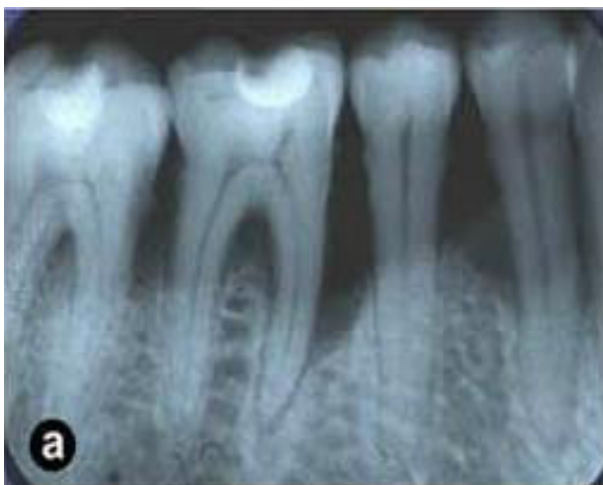
Figure 3. Case A. X-Ray images before treatment (a) and six months after (b)

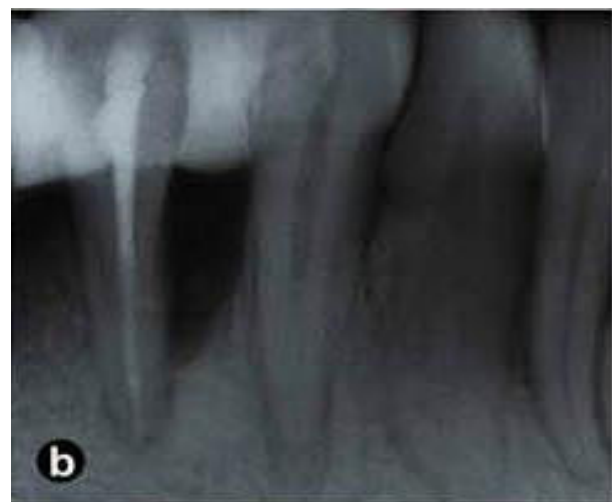
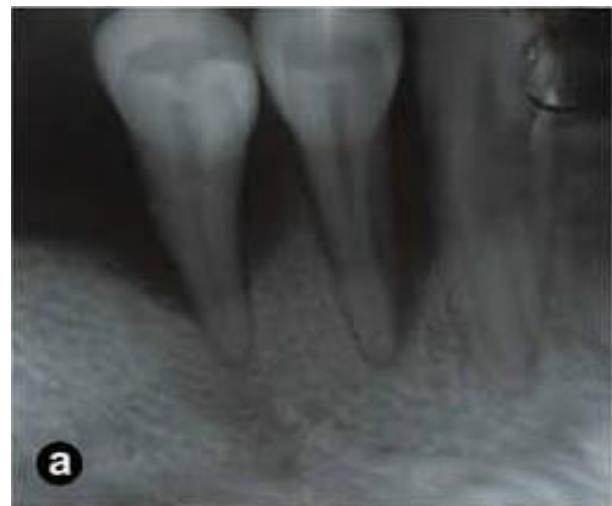

Figure 3. Case B. X-Ray images before treatment (a) and six months after (b)

DISCUSSION

The results of this case-series have indicated that the treatment of deep intrabony defects with OCHS and α -TriCalcium Phosphate could lead to statistically and clinically significant reductions of the periodontal probing depths and clinical attachment level gains. The observation that neither allergies nor infections occurred could signify that the combination of the two materials is well tolerated. These findings correlate with results of various studies relating the lack of allergic or foreign body reactions in both OCHS¹ and α -TCP.^{29, 30}

Methodologically, the analysis of the results of the treatment with the combination OCHS + α -TCP could be evaluated with regard to the treatment of intrabony defects by mean of the combination of enamel matrix proteins (EMD) and bovine-derived xenografts (BDX) or bioactive glasses. There are many similarities between the two therapeutical approaches: both single treatment modalities (OCHS and EMD)

are considered to be “biologic”, both products have a fluidity that may necessitate the combination with a bone graft to prevent the collapse of the flaps and both approaches require a good stability of the wound for a favorable outcome. The combinations of EMD with alloplasts as bioactive glasses^{33,34} or the bovine-derived xenograft Bio-Oss®^{35,36} have been tried and evaluated in controlled clinical and histological studies. Observations from animal-histological and human-histological studies demonstrated periodontal regeneration after treatment of intrabony defects with some of these combinations³⁷⁻⁴¹. However, data from clinical studies present a large variability and failed to draw definitive conclusions on the possible clinical benefit of a combination therapy in relation to single therapies.^{34,35,42-44}

Beta-TriCalcium Phosphate (β -TCP) has been used in a series of case reports for the treatment of periodontal osseous lesions.^{25,45-47} After variable time intervals, a significant gain of bone was observed by means of re-entry or radiographs. However, there is no controlled study comparing the result of α -TCP grafting with that of open flap debridement, and histology data from animal^{48,49} and human studies^{29,30,47,50,51,52} showed that α -TCP is rapidly resorbed or encapsulated by connective tissue, with minimal bone formation and no periodontal regeneration.

Treatment of intrabony defects with α -TCP resulted in an average of 2.3 mm CAL gain. Osteogenesis, cementogenesis, or connective attachment formation could not be identified. Instead, the slow-resorbable TCP particles (functioning as inert filling material) were tightly encapsulated in gingival connective tissue. The lack of bone and conjunctive attachment formation led to the conclusion that TCP has only a reduced effect on repair of the defect.⁴⁷

α -TCP is an alloplast with osteoconductive capacities⁵³, documented to be faster resorbable than β -TCP in closed bone defects⁵⁴⁻⁵⁹. α -TCP has been documented so far in a clinical study that has found average PD reductions of 2.42 ± 2.50 mm and CAL gains of 1.25 ± 2.22 mm at 6 months after the treatment of intrabony defects.¹⁴

On the other hand, treatment of intrabony defects with OCHS alone resulted in an average PD reduction of 5.33 ± 1.40 mm and a CAL gain of 4.4 ± 1.40 mm CAL.⁶ So, the average CAL gains achieved in our study by the combination OCHS + α -TCP are smaller than the average CAL gains achieved by the OCHS alone, but largely greater than the average CAL gains obtained by using the α -TCP alone. These results should probably be compensated by the stability of the wound achieved primarily by using the combination OCHS

+ α -TCP and by increased resorption capacity of the α -TCP.

A comparison with the already published results of the monotherapeutic approaches OCHS or TCP may be rendered difficult by the differences in the initial morphology of the defects. The majority of the defects taken into account in the present study displayed a combined 1-2 -walls configuration, known as having a worse healing prognosis than the defects with 2-3 walls.⁶¹⁻⁶³

The relatively marked CAL gain noted in this study could testify for the wound-stabilizing effect of the bone replacement material and could emphasize the clinical relevance of the combined therapy. The already described biological and clinical characteristics of OCHS and α -TCP could offer some practical advantages in deep defects when compared with the GTR-technique or with the combination of GTR plus a bone replacement material, when an exposure of the membrane could be a major inconvenience. The combination of OCHS and α -TCP could positively influence the wound healing as well, as suggested by the postoperative evolution of the cases. Indeed, no complications as abscesses or infections occurred postoperatively. However, the effect of the antibiotics on this particular positive outcome cannot be excluded.

Antibiotics are being prescribed in most of the clinical studies on regenerative periodontal therapies⁶⁴⁻⁶⁶, however, the literature has no defined position on the influence of the antibiotic adjunctive postoperative medication⁶⁷. More clinical controlled studies might be needed to elucidate the real need of postoperative antibiotics following regenerative periodontal treatments. More histological studies are also needed in order to determine if the observed clinical results represent a true periodontal regeneration rather than a simple defect fill.

CONCLUSIONS

The results of the case report indicate that treatment of deep intrabony defects using an oily Calcium Hydroxide suspension combined with α -TCP can lead to a statistically and clinically significant reduction of the PD and CAL gain. The lack of allergic or infectious reactions indicates that the combination of the two materials, while stable and very well tolerated, benefits from the anti-inflammatory and possible osteostimulative action of the oily suspension of Calcium Hydroxide. As histological evidences of the healing obtained by this therapy are still expected, further validation of this combination in treatment of

deep intrabony lesions will need controlled clinical studies, in order to elucidate whether this approach can improve the clinical outcomes, when compared to each single treatment.

REFERENCES

- Dietz G, Bartholmes P, Dietz G-H, et al. Calcium Hydroxide and Bone Regeneration. Odontological Aspects of Induced Osteogenesis in Experiment and Clinical Practice. Monography. 1998; Byblos Verlag, Munich.
- Stratul S, Rusu D, Jianu R, et al. Densitometric evaluation of periapical bone healing using an oily Calcium hydroxide suspension. A preliminary controlled study. Int Poster J Dent Oral Med 2004; Vol 6 No 03, Poster 236
- Dietz GH, Lazzarini L, Brunelli M, et al. Ist Osteoinductal® ein osteostimulatives Knochenersatzmaterial? Übersicht relevanter wissenschaftlicher Erkenntnisse - Teil 1. Biochemische, tierexperimentelle und klinische Untersuchungen. ZWR 2003; 112:9:395-9
- Merten HA, Dietz GH. Klinische Beobachtungen nach zahnärztlich-chirurgische Eingriffen bei Anwendung von Osteoinductal®. Teil 1: Tierexperimentelle Voruntersuchung. ZWR – Das Deutsche Zahnärzteblatt 1999;11:675-7
- Sculean A, Stavropoulos A, Windisch P, et al. Histologische Untersuchungen nach Behandlung von intraossären Knochendefekten mit Osteoinductal®. Parodontologie 2004; 15/3: 273-317:309, poster 39
- Stratul SI. Clinical studies on the treatment of intrabony defects using an oily Calcium Hydroxide suspension - Osteoinductal®. Inauguraldissertation zur Erlangung des Doktorgrades der Zahnmedizin der Johannes-Gutenberg-Universität Mainz dem Fachbereich Medizin. Mainz, 2004.
- Terheyden H, Jepsen S. Hartgeweberegeneration durch Wachstumsfaktoren und morphogene Proteine. Grundlagen und klinische Anwendung. Implantologie 1999;4:359-78
- Stratul SI, Sculean A, Willershausen B. Oily Calcium Hydroxide suspension vs. flap surgery in treating deep intrabony defects. Parodontologie 2004; 15/3: 273-317:309, poster 48
- Stratul SI, Rusu D, Benta A, et al. Clinical comparison between an oily Calcium Hydroxide suspension (Osteoinductal®) and an enamel matrix protein derivate (Emdogain®) for the treatment of intrabony periodontal defects in humans. Presentation at the 12. Annual Meeting of The New Working Group in Periodontology (NagP), Mainz, 23.10.2004.
- Trombelli L, Heitz-Mayfield L, Needleman I, et al. A systematic review of of graft materials and biological agents for periodontal intraosseous defects. J Clin Periodontol 2002; 29 (Suppl.3):117-135
- Selvig KA, Kersten BG, Chamberlain ADH, et al. Regenerative surgery of intrabony periodontal defects using e-PTFE barrier membranes: scanning electronmicroscopic evaluation of retrieved membranes vs. clinical healing. J Periodontol 1992;63:974-978
- Nowzary H, Matian F, Slots J. Periodontal pathogens on polytetrafluorethylene membrane for guided tissue regeneration inhibit healing. J Clin Periodontol 1995;22:469-474
- Stratul, S. I., Sculean, A., Willershausen, B. Oily calcium hydroxide suspension vs. flap surgery in treating deep intrabony defects. Parodontologie 2004; 15/3: 273-317:315, poster 48.
- Stratul, S., Sculean A. Oily Calcium Hydroxide plus alpha-TCP in treating intrabony defects. J Clin Periodontol 2003; 30 (Suppl. 4) : 71. Poster 273.
- Stratul, S-I. Treatment of intrabony defects with alpha-TCP and Calcium Hydroxide suspension. A 14-case report. Int Poster J of Dent Oral Med. 2004; Vol 5 No 01, Poster 216
- Stratul, S-I., Sculean, A. Oily calcium hydroxide suspension and alpha-TCP in treating intrabony defects. Int Poster J Dent Oral Med 2004; Vol 6 No 03, Poster 235
- Dragoo M, Sullivan M. A clinical and histologic evaluation of autogenous iliac bone grafts in humans. Part I. Wound healing 2-8 months. J Periodontol 1973; 44: 599-612
- Schallhorn R, Hiatt W. Human allografts of iliac cancellous bone and marrow in periodontal osseous defects (II). Clinical observations. J Periodontol 1972; 43: 67-81
- Brunsvold MA, Mellonig J. Bone grafts and periodontal regeneration. Periodontology 2000 1993; 1: 80-91
- Jarcho M. Biomaterial aspects of calcium phosphates. Dental Clinics of North America 1986; 30:25-47.
- Metsger DS, Driskell TD, Paulsrud JR. Tricalcium phosphate ceramic- a resorbable bone implant: review and current status. JADA 1982; 105:1035-1038.
- Bhaskar SN, Cutright DE, Knapp MJ, et al. Tissue reaction to intrabony ceramic implants. Oral Surg Oral Med Oral Pathol 1971; 31:282-289.
- Levin MP, Getter L, Adrian J, et al. Healing of periodontal defects with ceramic implants. J Clin Periodontol 1974;1:197-205.
- Levin MP, Getter L, Cutright DE, et al. A comparison of iliac marrow and biodegradable ceramic in periodontal defects. J Biomed Mat Res 1975; 9:183-195.
- Nery EB, Lynch KL, Kirthe WM, et al. Bioceramic implants in surgically produced infrabony defects. J Periodontol 1975; 46:328-347.
- Cameron HU, MacNab I, Pilliar RM. Evaluation of a biodegradable ceramic. J Biomed Mat Res 1977; 11:179-86.
- McDavid PT, Bone ME, Kafrawy AH, et al. Effect of autogenous marrow and calcitonin on reactions to a ceramic. J Dent Res 1979; 58:1478-83.
- Nery EB. Preliminary clinical studies of bioceramics in periodontal osseous defects. J Periodontol 1978;49:523-527.
- Stahl S, Froum S. Histologic evaluation of human intraosseous healing responses to the placement of tricalcium phosphate ceramic implants. I. Three to eight months. J Periodontol 1986; 57:211-7.
- Froum S, Stahl SS. Human intraosseous healing responses to the placement of tricalcium phosphate ceramic implants. II. 13 to 18 months. J Periodontol 1987;58:103-9.
- Caton J, Nyman S, Zander H. Histometric evaluation of periodontal surgery. II. Connective tissue attachment levels after four regenerative procedures. J Clin Periodontol 1980;7:224-231.
- Stahl SS, Froum SJ. Histologic and clinical responses to porous hydroxyapatite implants in human periodontal defects: Three to twelve month postimplantation. J Periodontol 1987;58:689-95.
- Sculean A, Berakdar M, Arweiler N, et al. Behandlung intraossärer Defekte mit Schmelzmatrix-Proteinen und bioaktivem Glas - Ein Bericht über zehn Fälle. Parodontologie 2000;3:231-240.
- Sculean A, Barbé G, Chiantella GC, et al. Clinical evaluation of an enamel matrix protein derivate combined with a bioactive glass for the treatment of intrabony periodontal defects in humans. J Periodontol 2002;73:401-8.
- Sculean A, Chiantella GC, Windisch P, et al. Clinical evaluation of an enamel matrix protein derivative (Emdogain), combined with a bovine derived xenograft (Bio-Oss), for the treatment of intrabony periodontal defects in humans. Int J Periodontol Rest Dent 2002;22:259-67.
- Sculean A, Windisch P, Keglevich T, et al. Clinical and histologic evaluation of human intrabony defects treated with an enamel matrix protein derivative combined with a bovine-derived xenograft. Int J Periodontol and Rest Dent 2003;23:47-55.
- Sculean A, Donos N, Reich E, et al. Healing of recession-type defects following treatment with enamel matrix proteins or guided tissue regeneration. A pilot study in monkeys. Journal de Parodontologie & d'Implantologie Orale 2000;19:19-31.
- Sculean A, Donos N, Brex M, et al. Treatment of intrabony

- defects with enamel matrix proteins and guided tissue regeneration. An experimental study in monkeys. *J Clin Periodontol* 2000;27:466-72.
39. Sculean A, Windisch P, Keglevich T, et al. Clinical and histologic evaluation of human intrabony defects treated with an enamel matrix protein derivative combined with a bovine-derived xenograft. *Int J Periodontol Rest Dent* 2003;23:47-55.
 40. Sculean A, Windisch P, Keglevich T, et al. Clinical and histological evaluation of an enamel matrix protein derivative combined with a bioactive glass for the treatment of intrabony periodontal defects in humans. *Int J of Periodontol Rest Dent* 2004 (in press).
 41. Sculean A, Stavropoulos A, Windisch P, et al. Healing of human intrabony defects following regenerative periodontal therapy with a bovine derived xenograft and guided tissue regeneration. *Clin Oral Invest* 2004 (in press).
 42. Lekovic V, Camargo PM, Weinlaender M, et al. A comparison between enamel matrix proteins used alone or in combination with bovine porous bone mineral in the treatment of intrabony periodontal defects in humans. *J Periodontol* 2000;71:1110-1116.
 43. Scheyer ET, Velasquez-Plata D, Brunsvold MA, et al. A clinical comparison of a bovine derived xenograft used alone and in combination with enamel matrix derivative for the treatment of periodontal osseous defects in humans. *J Periodontol* 2002;73:423-432.
 44. Velasquez-Plata D, Scheyer ET, Mellonig JT. Clinical comparison of an enamel matrix derivative used alone or in combination with a bovine-derived xenograft for the treatment of periodontal osseous defects in humans. *J Periodontol* 2002;73:433-40.
 45. Strub JR, Gaberthüel TW, Firestone AR. Comparison of tricalcium phosphate and frozen allogenic bone implants in man. *J Periodontol* 1979;50:624-29.
 46. Snyder AJ, Levin MP, Cutright DE. Alloplastic implants of tricalcium phosphate ceramic in human periodontal osseous defects. *J Periodontol* 1984;55:273-7.
 47. Baldock WT, Hutchens LH Jr, McFall WT Jr, et al. An evaluation of tricalcium phosphate implants in human periodontal osseous defects in two patients. *J Periodontol* 1985;56:1-7.
 48. Levin MP, Getter L, Adrian J, et al. Healing of periodontal defects with ceramic implants. *J Clin Periodontol* 1974; 1, 197-205.
 49. Barney VC, Levin MP, Adams DF. Bioceramic implants in surgical periodontal defects. A comparison study. *J Periodontol* 1986; 57:764-70.
 50. Drago MR, Kaldahl WB. Clinical and histological evaluation of alloplasts and allografts in regenerative periodontal surgery in humans. *Int J Perio Rest Dent* 1983;3:8-29.
 51. Bowers DM, Varg JW, Lerg B, et al. Histologic observations following the placement of tricalcium phosphate implants in human intrabony defects. *J Periodontol* 1986;57:286-7.
 52. Saffar JL, Colombier ML, Detienville R. Bone formation in tricalcium phosphate-filled periodontal intrabony lesions. Histological observations in humans. *J Periodontol* 1990;61, 209-216.
 53. Thieme V, Müller E-I, Mägdefessel U, et al. Füllung zystischer Knochendefekte mit oberflächen-modifiziertem alpha-Tricalciumphosphat. *Deutsche Zeitschrift für Mund-, Kiefer-, und Gesichtschirurgie* 1988;12:18-24.
 54. Blume O, Krekeler G, Schilli W. Preparation of the implant site by local augmentation with alloplastic resorbable material. Reprint from 3rd Asian Congress on Oral and Maxillofacial Surgery, 1996;487-492.
 55. Blume O, Krekeler G, Schilli W. Indikationen und Beispiele für die Anwendung von α - Tricalciumphosphat als resorbierbarer, alloplastischer Knochenersatz. *Hefte zu der Unfallchirurgie* 1998;265:303-311.
 56. Ducheyne P, Radin S, King L. The effect of calcium phosphate ceramic composition and structure on in vitro behavior. 1. Dissolution. *J Biomed Mat Res-1993*;27:25-34.
 57. Horch HH, Steegmann B. Erfahrungen mit dem resorbierbaren TCP-Keramikgranulat zur Füllung größerer Knochendefekte nach Zystektomie im Kieferbereich. *Deutsche Zahnärztliche Zeitschrift* 1985;40:672-677.
 58. Wagner W, Tetsch P, Ackermann KL, et al. Tierexperimentelle Untersuchungen zur Knochen-regenerationen genormter Defekte nach der Implantation einer Trikalziumphosphat keramiken DZZ 1981;36:82-85.
 59. Wagner W, Wahlmann UW. Vergleichende Tierexperimentelle Untersuchungen zur Knochenregenerationen nach der Implantation verschiedener Kalziumphosphat-Keramiken. DZZ 1985;40:664-7.
 60. Stratul S, Sculean A. Oily Calcium Hydroxide plus α -TCP in treating intrabony defects. *J Clin Periodontol* 2003;30(Suppl.4):71. Poster 273.
 61. Cortellini P, Pini Prato G, Tonetti MS. Periodontal regeneration of human infrabony defects. I. Clinical measures. *J Periodontol* 1993;64:254-260.
 62. Tonetti MS, Pini Prato G, Cortellini P. Factors affecting the healing responses of intrabony defects following GTR and access flap surgery. *J Clin Periodontol* 1996;23:548-556.
 63. Polson AM, Heijl LC. Osseous repair in infrabony periodontal defects. *J Clin Periodontol* 1978;5:13-23.
 64. Heijl L, Heden G, Svardstrom G, et al. Enamel matrix derivative (Emdogain®) in the treatment of intrabony periodontal defects. *J Clin Periodontol* 1997;24:705-714.
 65. Sculean A, Reich E, Chiantella G, et al. Treatment of intrabony periodontal defects with an enamel matrix protein derivative (Emdogain®). A report of 32 cases. *Int J Periodontics Rest Dent* 1999;19:157-163.
 66. Sculean A, Donos N, Blaes A, et al. Comparison of enamel matrix proteins and bioabsorbable membranes in the treatment of intrabony periodontal defects. A split-mouth study. *J Periodontol* 1999;70:255-262.
 67. Vest TM, Greenvell H, Drisko C, et al. The effect of postsurgical antibiotics and a bioabsorbable membrane on regenerative healing in Class II furcation defects. *J Periodontol* 1999;70:878-87.