

# A RETROSPECTIVE ANALYSIS OF THE COMPLICATIONS DUE TO AMNIOCENTESIS - EVALUATION ON 232 CASES

Gheorghe Budau<sup>1</sup>, Alexandra Georgiana Budau<sup>2</sup>, Cezara Muresan<sup>1</sup>

## REZUMAT

**Introducere:** Amniocenteza este o procedură uzuală de diagnostic prenatal invaziv, pentru a obține cariotipul fetal. Sindromul Down este cea mai frecventă aneuploidie, cu importanță prin mortalitate și morbiditate. **Material și metode:** Am efectuat un studiu retrospectiv asupra complicațiilor materne și fetale pe un lot de 232 de amniocenteze genetice din perioada 14.06.2002-16.02.2009. De obicei acest procedeu este efectuat la vârsta gestațională de 16-20 SA. În studiul nostru, ca și în alte studii, cea mai frecventă indicație de amniocenteză a fost reprezentată de vârsta maternă  $\geq 35$  ani (90 de pacienți din totalul de 232; 38.79%). Complicațiile amniocentezei sunt rare (0.5-2%). **Rezultate:** Am semnalat aceleași complicații în cadrul grupului nostru comparativ cu datele din literatură. Am avut un singur caz de avort spontan în cadrul lotului nostru, la o gravidă de 17 SA + 6 zile, la 60 de ore după amniocenteză (0.43%). În 2 cazuri nu am obținut rezultate pozitive pentru culturile celulare (culturi negative: 0.86%). În 4 cazuri (1.72%) nu am putut aspira lichid amniotic ("puncție uscată"). Am înregistrat 6 cazuri de hemoragie intraamniotică activă - 2.58% și în toate situațiile a cula străbătut placenta. **Concluzii:** Considerăm că amniocenteza genetică este o metodă sigură de diagnostic prenatal invaziv, atât pentru mamă, cât și pentru făt. **Cuvinte cheie:** amniocenteză genetică, cariotip fetal, complicații fetale

## ABSTRACT

**Introduction:** Amniocentesis is a common procedure of prenatal invasive diagnosis used to assess fetal karyotype. Down syndrome is the most frequent chromosomal disease, due to its morbidity and mortality. **Material and methods:** We have performed a retrospective study of fetal and maternal complications that we have meta-analyzed after reviewing a number of 232 of genetic amniocentesis, during the period 14.06.2002-16.02.2009. Usually this procedure is performed between 16-20 WG. In our study, as in other studies, the most frequent indication was maternal age  $\geq 35$  years (90 patients from the total number of 232; 38.79%). The complications of amniocentesis are rare (0.5-2%). **Results:** We have registered the same complications in our group as compared to data from literature. The only case of spontaneous abortion (0.43%) in our group was in a patient: 17 WG + 6 days, at 60 hours after the procedure. We had negative cell cultures in 2 cases (0.86%). In 4 cases (1.72%) we could not aspirate amniotic fluid ("dry puncture"). We registered in 6 cases - 2.58%, an active intraamniotic hemorrhage and in all situations the needle has passed the placenta. **Conclusions:** We consider that amniocentesis is a safe method of prenatal diagnosis, for the mother and also for the fetus.

**Key Words:** genetic amniocentesis, fetal karyotype, fetal complications

## INTRODUCTION

Amniocentesis is a common procedure of prenatal invasive diagnosis, used in the whole world; for the first time it was used to assess the fetal sex in the 50's and then it entered in the clinical practice for karyotype determination from fetal cells.<sup>1</sup> Among chromosomal anomalies (genetic diseases, where a part of the genetic chain is broken), the Down syndrome is the most frequent disease, due to its morbidity and mortality.

The incidence of Down syndrome is 1:1,250 newborns from mothers aged around 20 years and 1:400 in mothers aged around 40 years. The prenatal diagnosis of trisomy 21 allows the parents to decide whether to continue or terminate the affected pregnancy.<sup>2</sup> Other common syndromes are trisomy 13, 18 and Turner syndrome.

The screening from the 1<sup>st</sup> trimester (nuchal translucency, free  $\beta$ -HCG in maternal serum and PAPP-A - also from maternal serum) and from the 2<sup>nd</sup> trimester (triple test:  $\alpha$ -fetoprotein, free  $\beta$ -HCG, non-conjugated estriol - all from maternal serum) and the age of the mother is often used for the detection of chromosomal abnormalities.

Generally an invasive genetic diagnosis is offered to a woman aged  $\geq 35$  years, in order to determine fetal karyotype, while for younger women (age  $< 35$  years) a not-invasive screening is discussed (ultrasound, biochemical markers from maternal serum).<sup>3</sup>

Maternal serum tests can identify 85% of the pregnancies at risk, with a false positive rate of 5%.

<sup>1</sup>Bega Clinic of Obstetrics and Gynecology, Victor Babes University of Medicine and Pharmacy, Timisoara, <sup>2</sup>Dept. of Obstetrics and Gynecology, Evang. Krankenhaus, Herne Bochum, Germany

Correspondence to:

Dr. Gheorghe Budau, Bega Clinic of Obstetrics and Gynecology, 12V. Babes Str., Timisoara, Tel. +40-7483-31320.  
Email: gheorghebudau@yahoo.com

Received for publication: Jun. 29, 2009. Revised: Nov. 16, 2009.

The final diagnosis needs chorionic villus sampling (CVS) or amniocentesis.

Genetic amniocentesis (2<sup>nd</sup> trimester) is the most common invasive technique that is performed due to its genetic safety and its low cost.<sup>4</sup> It is a relatively painless diagnostic procedure, performed in outpatient conditions, sometimes under local anesthesia; however, anesthesia doesn't reduce the maternal pain perception.<sup>5</sup>

Data from literature report that the frequency of the complications is variable, between 0.5-2.2%.<sup>6,7</sup>

The aim of this paper is to evaluate the fetal and maternal complications of a number of 232 amniocenteses performed in the Bega Clinic of Obstetrics and Gynecology, Timisoara.

## MATERIALS AND METHODS

We have performed a retrospective study of fetal and maternal complications that we have met after reviewing a number of 232 of genetic amniocentesis, during the period 14.06.2002 - 16.02.2009.

The indications for amniocentesis were different, including maternal age  $\geq 35$  years, a high risk detected at the screening in the 2<sup>nd</sup> trimester (abnormal triple test), elevated or low levels of  $\alpha$ -fetoprotein in maternal serum, the presence of ultrasound markers associated with chromosomal abnormalities, a former child with Down syndrome, fetal anomalies diagnosed in utero.

Amniocentesis was indicated when the result at the triple test showed a risk  $> 1:250$ . All pregnant women signed an informed consent before the procedure.

We had 3 twin pregnancies and 229 monofetal pregnancies.

We performed amniocentesis between 16-25 gestational weeks (GW), at patients aged 19-54 years.

Our ultrasound machines were Siemens SI 200, Esaote, Voluson 730Pro, with sectorial convex, linear and volumetric transducers, in order to perform ultrasound scan before amniocentesis, to localize the placenta and to have a continuous monitoring during the procedure in all cases.

The abdominal wall was aseptized with a betadine solution, then isolated with a sterile textile and we used sterile ultrasound gel. At the patient's request, we performed the procedure under local anesthesia with lidocain 1%.

The technique of amniocentesis was the type of "2 operators", "1 operator" and free-hand in all situations.

Our needles were spinal needles: 18; 19; 20; 22; 25 G, 9-15 cm length. We aspirated 1 ml for each week of pregnancy. The first 1-2 ml of amniotic fluid were

not used, in order to minimize the contamination of amniotic fluid with maternal serum or maternal cells.

We had no limitations regarding the transplacental or transamniotic passage.

Further information about the outcome of pregnancies were obtained from the patient herself, from the obstetrician and from the genetician.

Some patients received medication (tocolitic agents and antibiotics).

## RESULTS

Maternal age of our patients was between 19-54 years. Maternal age  $\geq 35$  years was the most frequent indication for amniocentesis (90 from 232 cases, 38.79%). Fetal karyotype was not obtained in only one case (0.41%), when the culture of cells was negative, but the patient did not repeat the procedure.

In one patient we had four passages of the needle in the same attempt.

Maternal and fetal complications have been registered in 232 cases as illustrated in the following table:

Table 1. Maternal and fetal complications after amniocentesis.

<b>Complication</b>	<b>No. Cases</b>	<b>%</b>
<b>Failure of aspiration "dry puncture"</b>	<b>4</b>	<b>1.72</b>
<b>Negative cell culture</b>	<b>2</b>	<b>0.86</b>
<b>Abortion</b>	<b>1</b>	<b>0.43</b>
<b>Amniotic fluid leakage</b>	<b>1</b>	<b>0.43</b>
<b>Active intramniotic hemorrhage</b>	<b>6</b>	<b>2.58</b>
<b>Fetal skin injury</b>	<b>1</b>	<b>0.43</b>
<b>TOTAL</b>	<b>15</b>	<b>6.46</b>

The only case of spontaneous abortion (0.43%) in our group was in a patient: 17 WG + 6 days, at 60 hours after the procedure. The woman was of 34 years age and had as associated feature a myoma. The fetal karyotype was normal. In this case the patient has neglected the medical advice for the status post-amniocentesis.

We had negative cell cultures in 2 cases (0.86%). One of these cases was the result of a transplacental passage of the needle and the amniotic fluid was serohaematic. The other negative cell culture resulted from a transamniotic needle passage. In the first case we repeated the procedure and the culture was positive. In the 2<sup>nd</sup> case the patient refused a new attempt, so we had no cytogenetic result.

In 4 cases (1.72%) we could not aspirate amniotic fluid ("dry puncture"). At 3 patients from these 4 the

fetus has blocked the tip of the needle and at the 4th patient we observed the “tenting effect”. In all these 4 cases we performed a second amniocentesis with another site of puncture and it was successful in all situations.

We registered in 6 cases – 2.58%, an active intraamniotic hemorrhage and in all situations the needle has passed the placenta. At 2 patients the hemorrhage was observed during the procedure and in 4 cases – after the withdrawal of the needle from the uterus, at the site where the needle passed the placenta. At all patients the duration of bleeding was < 15 seconds. (Fig. 1)

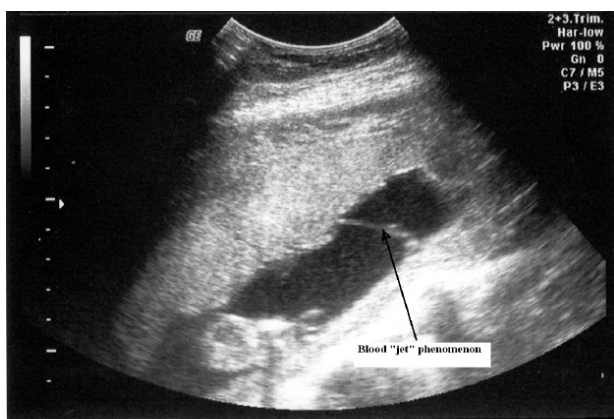


Figure 1. Intraamniotic bleeding after the needle withdrawal.

In one patient (0.43%) we had amniotic fluid loss through the vagina and it spontaneously stopped during 24 hours.

We have observed only at one patient (0.43%) from the total number of 232 of amniocentesis a fetal skin injury, caused by the stitch of the needle tip into the fetal leg. The fetal injury was linked to the amniocentesis at 4 years after this procedure was performed.

We had no infections in our group of patients.

## DISCUSSIONS

Amniocentesis is a method of invasive prenatal diagnosis, commonly used around the world and it allows the diagnosis of a great number of genetic and chromosomal disorders of the fetus. This method is used in practice to determine the fetal karyotype from amniotic fluid.<sup>8</sup> Usually this procedure is performed between 16-20 WG.<sup>9</sup> In our study, as in other studies, the most frequent indication was maternal age  $\geq$  35 years (90 patients from the total number of 232; 38.79%).<sup>9</sup>

The complications of amniocentesis are rare (0.5-2%) and are represented by vaginal bleeding, uterine contractions, vaginal loss of amniotic fluid,

intrauterine infections, fetal harm, abortion or intrauterine fetal death.<sup>6,10</sup>

The percentage of vaginal bleeding and amniotic fluid leakage is low, the amniotic fluid loss are about 1-2%.<sup>7,11</sup>

Amniotic fluid loss is of small amount and stops spontaneous, usually amniotic fluid recovers in the next 12 - 48 hours, during this time the patient is advised to bed rest and to inform her obstetrician if vaginal bleeding or uterine contractions appear.

If in the first 5 days after amniocentesis the amniorrhea does not stop spontaneously, the recommended treatment is the blood clot path. It is known that a continuous amniotic fluid loss, for a longer period can be complicated with an abnormal development of fetal lungs, of extremities, with infections, with premature birth or abortion.<sup>12</sup> In our group of patients we had only one case (0.43%) of amniotic fluid loss from all the cases.

In some situations the needle for the puncture cannot pass the amniotic membrane, which is only separated from the uterine wall; it is the so called “tenting effect”. It is the case of a dry puncture, when no fluid can be aspirated. Diagnosis is made by the fact that the tip of the needle is seen in amniotic fluid but no fluid can be aspirated. This phenomenon has been found to be associated with chromosomal anomalies (Down, others), but is also seen in early performed amniocentesis (<15 WG).<sup>9,13</sup>

In our study we have seen the tenting effect in one case, associated with advanced maternal age, but the fetal karyotype was normal (46XY). We could not determine any relationship between this event and abnormal chromosomes, maybe due to our small number of cases.

In our 4 cases of dry puncture (1.72%) at 3 of them we observed together with the tenting effect also a position of the fetus that blocked the access of the needle. In all cases we had to proceed to a new needle passage, which was successful.

The result from the culture cells of the total number of 232 of amniocentesis showed in 2 cases (0.86%) the failure of positive result. Amniotic fluid in one case was clear and in the second case was contaminated with blood. Data from literature show that the results of negative culture are very different. On a group of 903 cases, Williamson et al (1985) have reported a percentage of 0.2%; 2 patients needed a second amniocentesis.<sup>14</sup>

When amniotic fluid has an abnormal color (brown or green) the incidence of negative culture is between 0% (Golbus, 1979) and 20 % (King, 1978).<sup>15,16</sup>

In the situation of negative culture there is

necessary to repeat amniocentesis or to perform cordocentesis, in order to obtain fetal karyotype. In our group a second amniocentesis was performed after 7 days from the first attempt in one of the cases with negative culture. This time it was a positive culture but the amniotic fluid was as in the first time contaminated with blood. At the second patient the next amniocentesis could not be repeated because she refused it.

Our rate of success in the meaning of positive cultures was 99.13%, compared to data from literature: 98%.<sup>4</sup>

Active intraamniotic bleeding was observed in 6 cases (2.58%) and in all cases the needle has passed the placenta during the procedure. In all situations at the withdrawal of the needle we observed a pulsatile bleeding at the site of the puncture. After 5-10 seconds, the hemorrhage could not be observed anymore. None of the patients had other complications.

Perkes et al (1983) have described intraamniotic bleeding in situations where the needle passes the placenta and considered that the bleeding was of little importance and not associated with aspirated blood or with complications of pregnancy.<sup>17</sup> In our group we had in 1 case blood at the aspiration of amniotic fluid and at the other 5 cases amniotic fluid was serous, clear.

The rate of abortion is about 1:400 to 1:200.<sup>11,18,19</sup> Odibo et al have reported an incidence of 0.13% (1/769) fetal loss related to amniocentesis; Mungen et al (2006) have reported an incidence of 2.3% fetal loss; Bettelheim et al (2002) have reported a pregnancy loss of 0.74%.<sup>20-22</sup>

Direct fetal damage caused by the needle during amniocentesis is very rare, but there are cases described in literature when fetal skin injury or severe organ damage have been seen.

The real incidence of fetal skin injury is not known, but before the development of ultrasound in real time, they were reported about 0.1- 9%.<sup>23</sup> Skin scar is usually a point or can be linear, of 1-2 mm, a small depression in the skin. At 4 years after amniocentesis, at a child (1 case - 0.43%), a little skin scar on the leg was recognized to be related to the amniocentesis performed during pregnancy.

## CONCLUSIONS

Due to the nature of complications and their incidence, compared to data from literature, although our group is relative small, we consider that amniocentesis is a safe method of prenatal diagnosis, for the mother and also for the fetus.

## REFERENCES

1. Guven MA, Ceylaner S: Prenatal diagnosis with amniocentesis and cordocentesis: evaluation of 181 cases. *Perinatoloji Derjizi* 2005;13(1):25-30
2. Newberger SD: Down syndrome: Prenatal risk assessment and diagnosis. *Am Fam Physician* 2000;62:825-34
3. Clerici G, Donti E, Zacutti A, Di Renzo GC: Prenatal diagnosis in Italy. *Eur J Hum Genet* 1997;5(suppl 1):42-47
4. Osmanağaoğlu M, Bayram C, Bozkaya H. Retrospective analysis of genetic amniocentesis: evaluation of 189 cases. *Int J Gyn Obst* 2008;9(1).
5. Gordon CM, Ventura-Braswell Ada, Higby K, et al. Does local anesthesia decrease pain perception in women undergoing amniocentesis? *Am J Obstet Gynecol* vol 196, issue 1, 2007: p55 e1 – 55 e4.
6. Blessed WB, Lacoste H, Welch RA.: Obstetrician-gynecologists performing genetic amniocentesis may be misleading themselves and their patients. *Am J Obstet Gynecol.* 2001 Jun;184(7):1340-2; discussion 1342-4
7. Reid KP; Gurrin LC; Dickinson JE; Newnham JP; Phillips JM: Pregnancy loss rates following second trimester genetic amniocentesis, *Aust N Z J Obstet Gynaecol.* 1999 Aug;39(3):281-5
8. Steele MW, Breg WR Jr. Chromosome analysis of human amniotic-fluid cells. *Lancet.* 1966 Feb 19;1(7434):383-385
9. Tongsong T; Wanapirak C; Sirivatanapa P; et al. Amniocentesis-related fetal loss: a cohort study. *Obstet Gynecol* 1998 Jul;92(1):64-7
10. Copel JA, Pettker CM: *Ultrasound Clinics: Amniocentesis: technique and complications*, *Contemporary Ob Gyn*, 2005
11. Tabor A, Philip J, Madsen M et al., Randomized controlled trial of genetic amniocentesis in 4606 low risk women. *Lancet* 1 (1986), p. 1287-93
12. Sener T, Ozalp S, Hassa H, Yalçın OT, Polay S. Maternal blood clot patch therapy: a model for postamniocentesis amniorrhea. *Am J Obstet Gynecol.* 1997 Dec;177(6):1535-6
13. Leung WC, Waters JJ, Chitty L. Prenatal diagnosis by rapid aneuploidy detection and karyotyping: a prospective study of the role of ultrasound in 1589 second-trimester amniocenteses. *Prenat Diagn.* 2004 Oct;24(10):790-5
14. Williamson RA, Varner MW, Grant SS: Reduction in amniocentesis risks using a real-time needle guide procedure. *Obstet Gynecol* 1985;65:751-755
15. Golbus MS, Loughman WD, Epstein CJ, et al. Prenatal genetic diagnosis in 3000 amniocenteses. *N Engl J Med*, 300:157, 1979
16. King CR, Prescott G, Pernoll M. Significance of meconium in midtrimester diagnostic amniocentesis. *Am J Obstet Gynecol.* 1978 Nov 15;132(6):667-9
17. Perkes EA, Baim RS, Clair MR, Goodman K, Allen RE. Intrauterine bleeding following transplacental amniocentesis. *J Ultrasound Med.* 1983 Feb;2(2):55-7
18. CEMAT Group. Randomised trial to assess safety and fetal outcome of early and midtrimester amniocentesis. The Canadian Early and Mid-trimester Amniocentesis Trial (CEMAT) Group. *Lancet.* 1998 Jan 24;351(9098):242-7
19. Kozłowski P, Knippel A, Stresig R. Individual risk of fetal loss following routine second trimester amniocentesis: a controlled study of 20,460 cases. *Ultraschall Med.* 2008 Apr;29(2):165-72
20. Odibo AO, Gray DL, Dicke JM, et al. Revisiting the fetal loss rate after second-trimester genetic amniocentesis: a single center's 16-year experience. *Obstet Gynecol.* 2008 Mar;111(3):589-95
21. Mungen E, Tutuncu L, Muhcu M, et al. Pregnancy outcome following second trimester amniocentesis: a case-control study. *Am J Perinatol.* 23(1): 25-30, 2006
22. Bettelheim D, Kolinek B, Schaller A, Bernaschek G: Complication rates of invasive intrauterine procedures in a centre for prenatal diagnosis and therapy. *Ultraschall Med.* 2002, 23(2): 119-22
23. Vilar Coromina N, Villa AV, Puigarnau Vallhonrat R., et al. Skin dimpling : A complication of amniocentesis. *Anales de pediatria*, 2007, vol. 66, no4, [Note(s): 335, 407-409